

IMET 2000 PAL

International Medical Education Trust - Palestine

LAPAROSCOPIC HERNIOPLASTY

DR ABDALLAH AHWARI , MD

MRCSE

- ▶ Inguinal hernioplasty has undergone a gradual evolution over the last 100 years. In the beginning, surgeons like **Edoardo Bassini**, **William Halsted**, and **Chester McVay** championed new understandings of hernia anatomy and fresh approaches to dissection and repair of the inguinal floor

- ▶ In the 1970s surgeons began to incorporate prosthetic materials into their repairs to eliminate tension and to decrease recurrence

- ▶ Later Nyhus, Stoppa, and Wantz further changed the direction of inguinal hernioplasty by applying prostheses to the posterior wall of the groin.

- ▶ The evolution reached its current level in 1990 shortly after the introduction of laparoscopic cholecystectomy, when the laparoscopic approach to inguinal hernia repair was introduced.

TERMS TO KNOW

- ▶ **TEP:** totally extraperitoneal approach .
- ▶ **TAPP** :transabdominal preperitoneal approach
- ▶ **IPOM:** intraperitoneal “on-lay” technique

IMET 2000 PAL
International Medical Education Trust – Palangeme
www.imet2000-pal.org

TEP

IMET 2000 PAL
International Medical Education Trust – Palestine
www.imet2000-pal.org

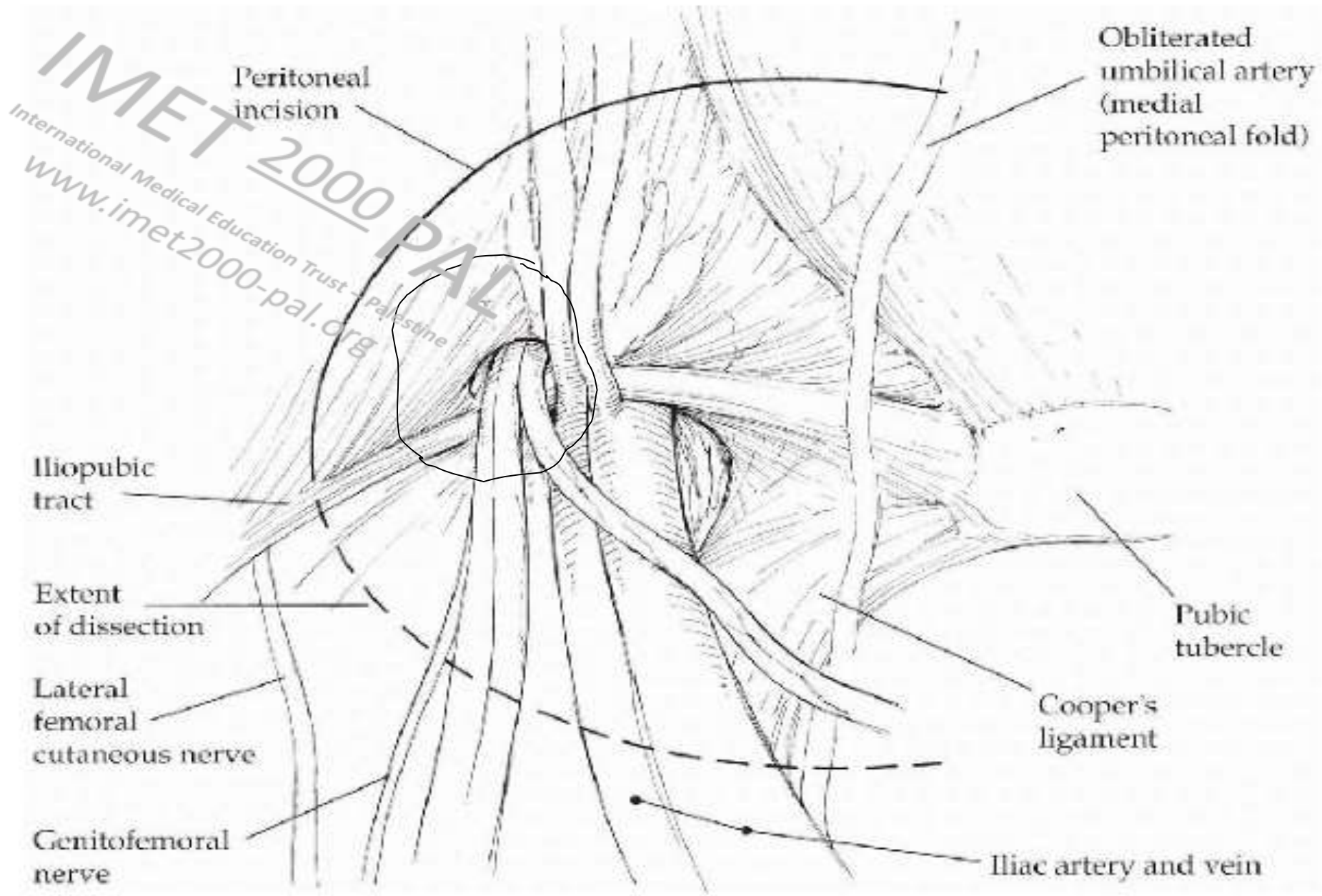
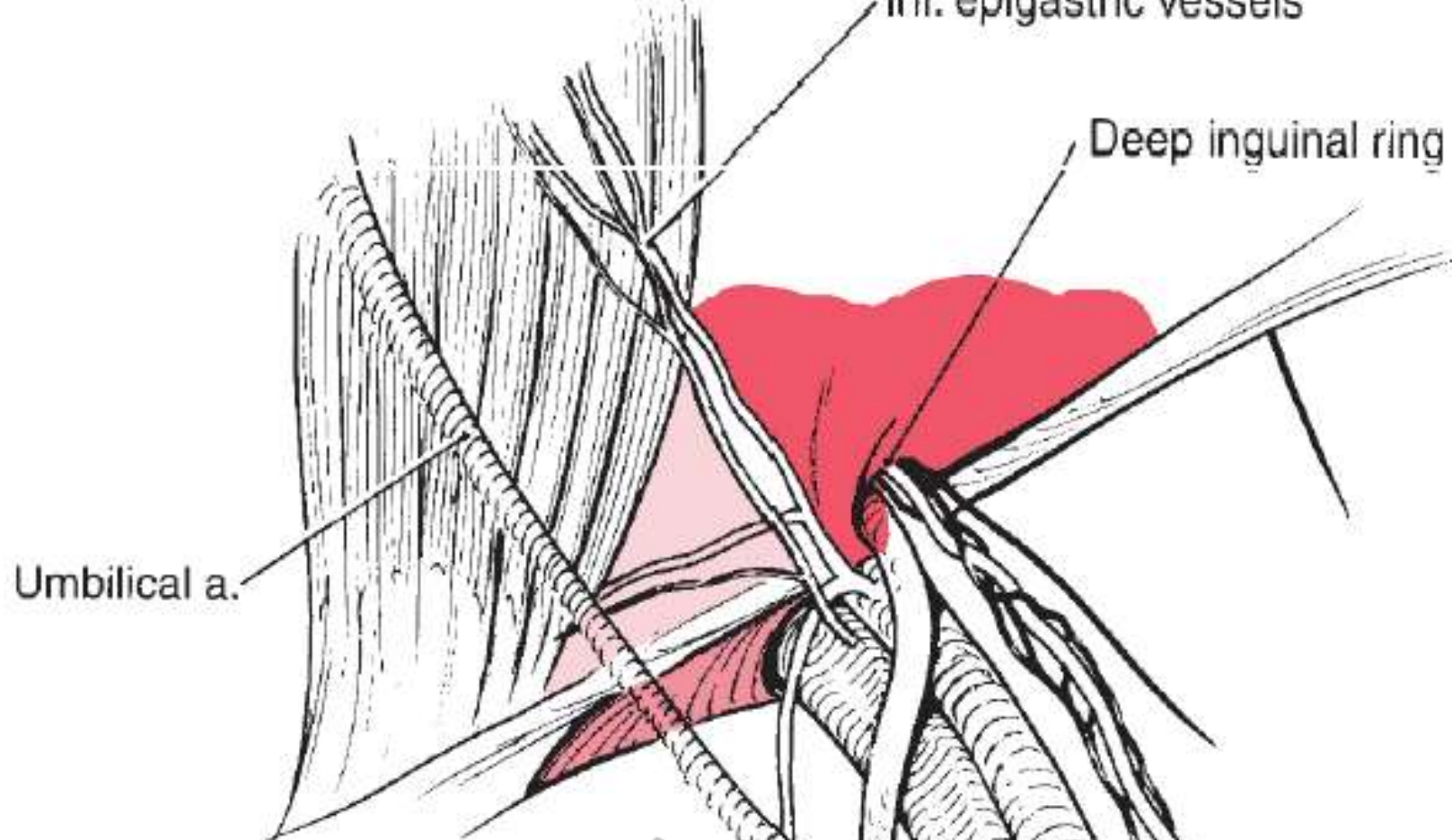





Fig. 53-1. Peritoneal incision in a left-sided transabdominal preperitoneal (TAPP) hernia repair.



-  Direct space
-  Femoral space
-  Indirect space

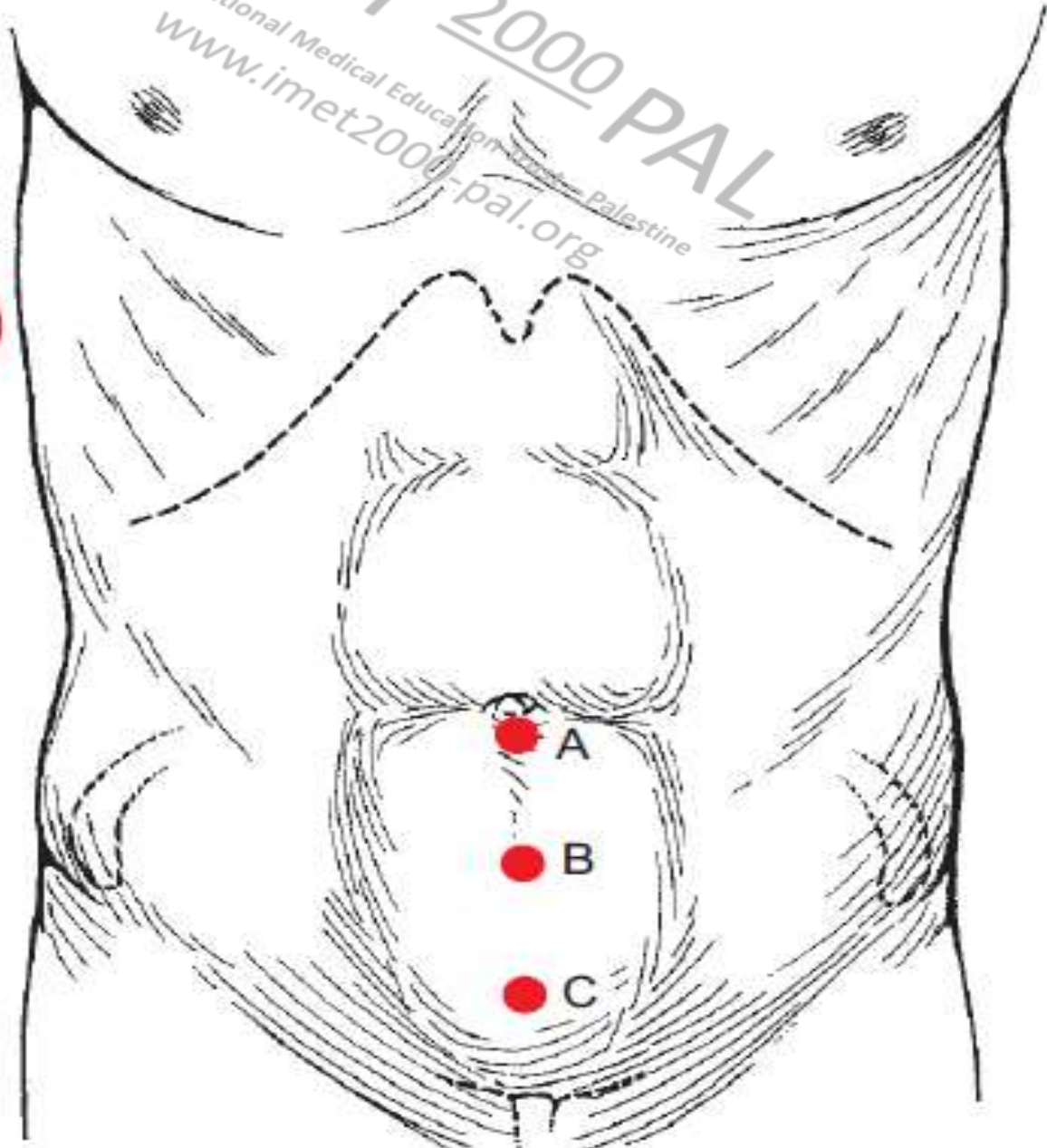
IMET 2000 PAL
International Medical Education Trust - Palestine
www.imet2000-pal.org

IMET 2000 PAL

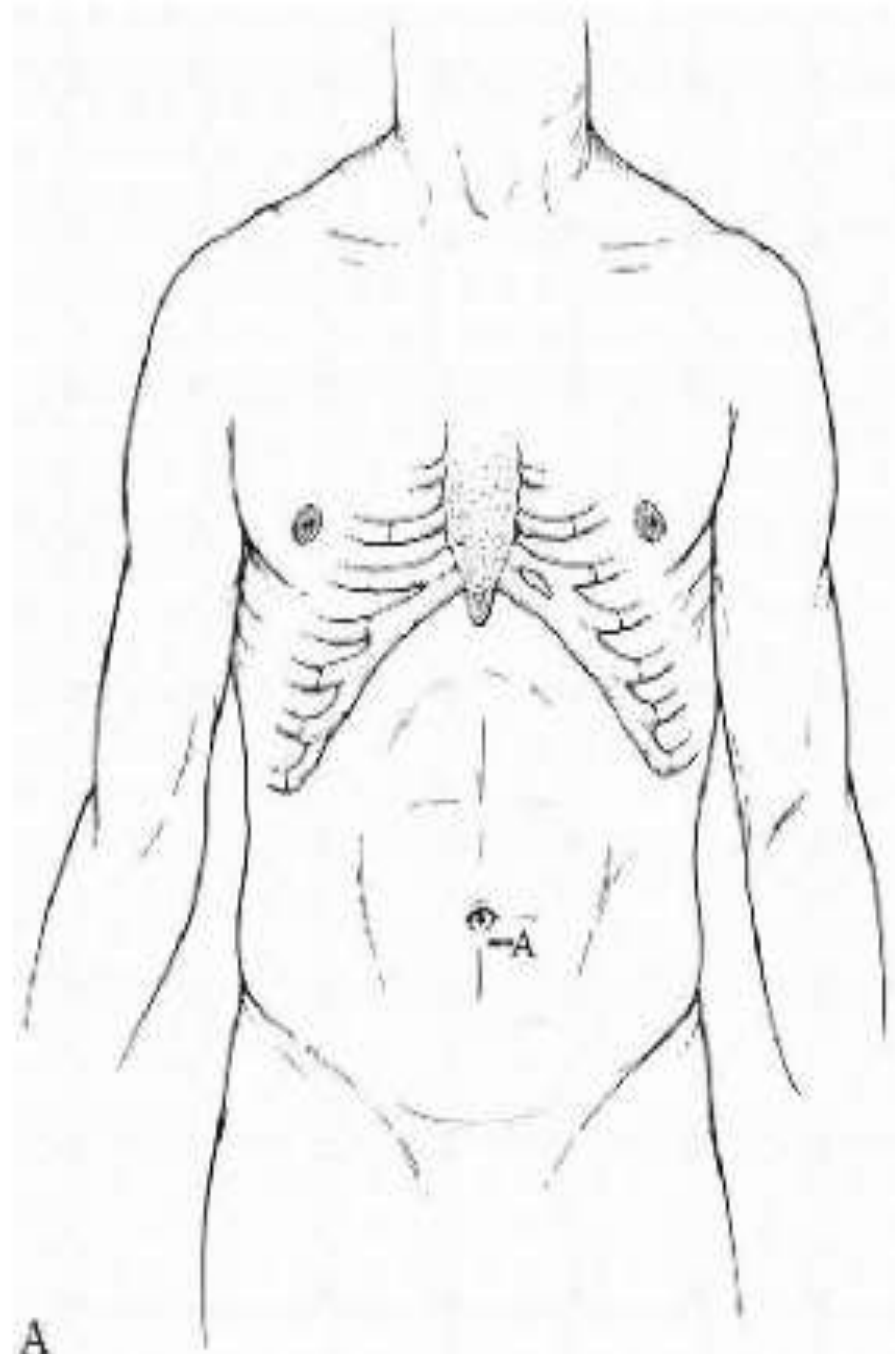
International Medical Education on Trauma - Palestine
www.imet2000-pal.org

S

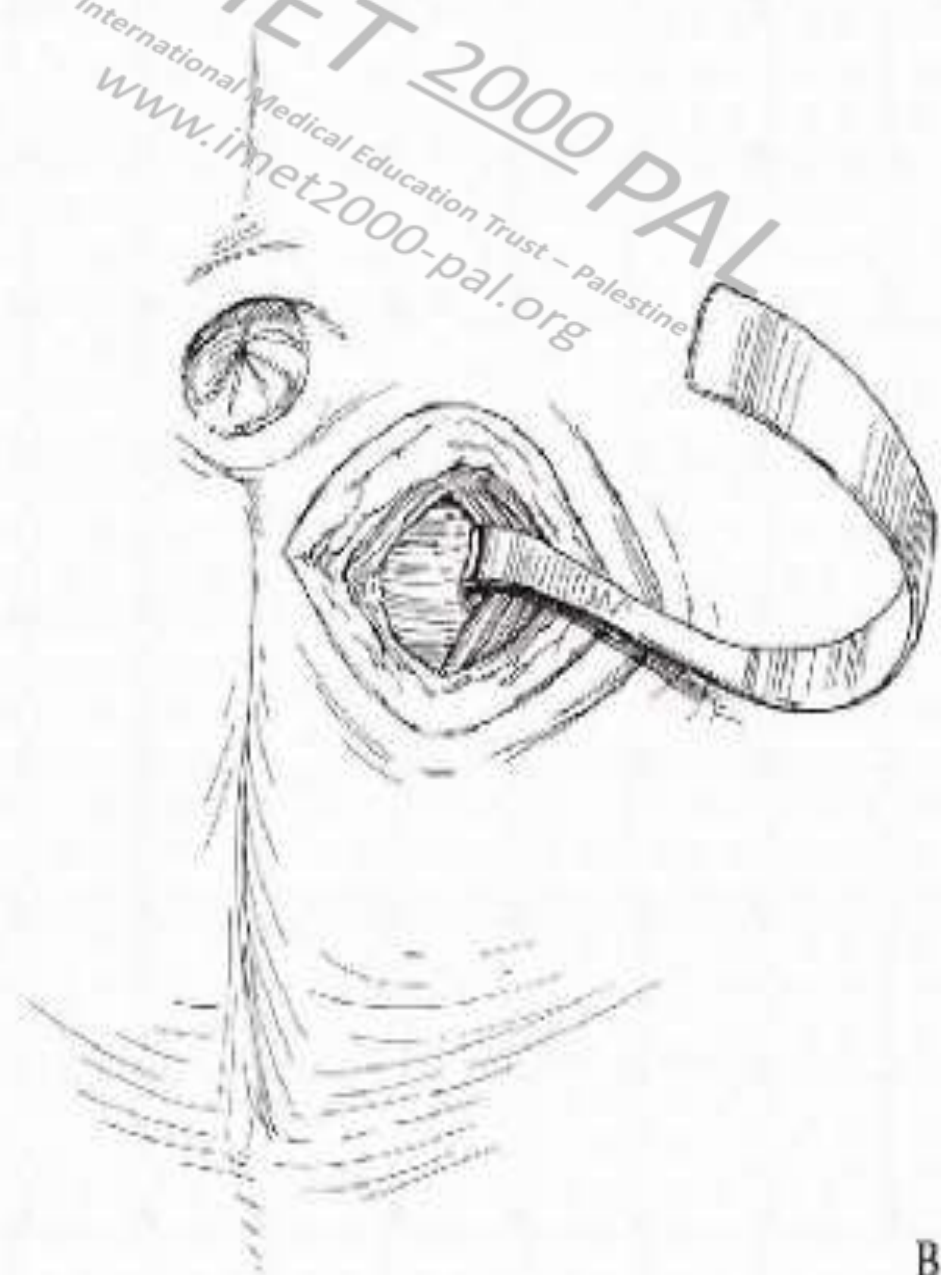
CA



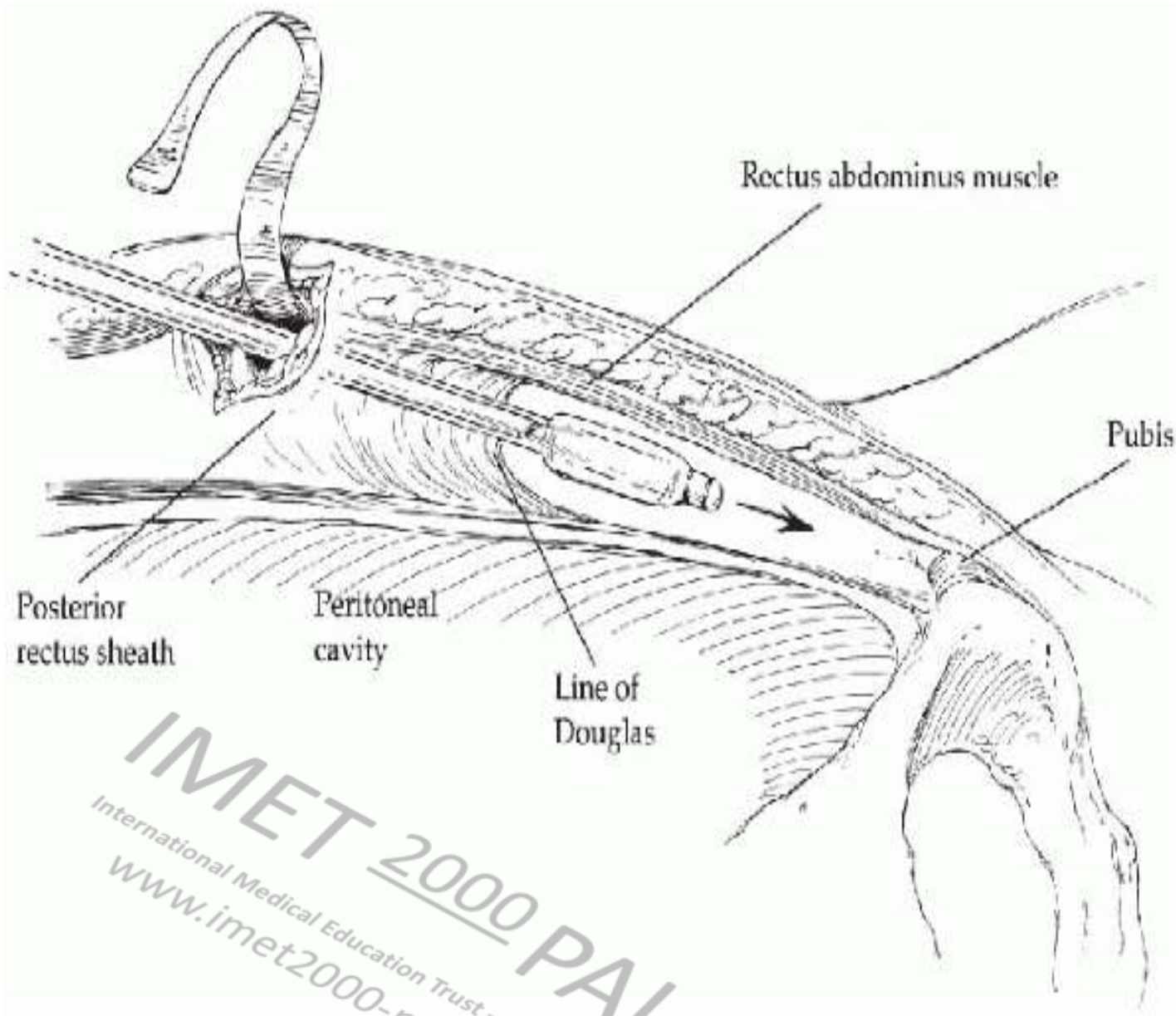
b



A



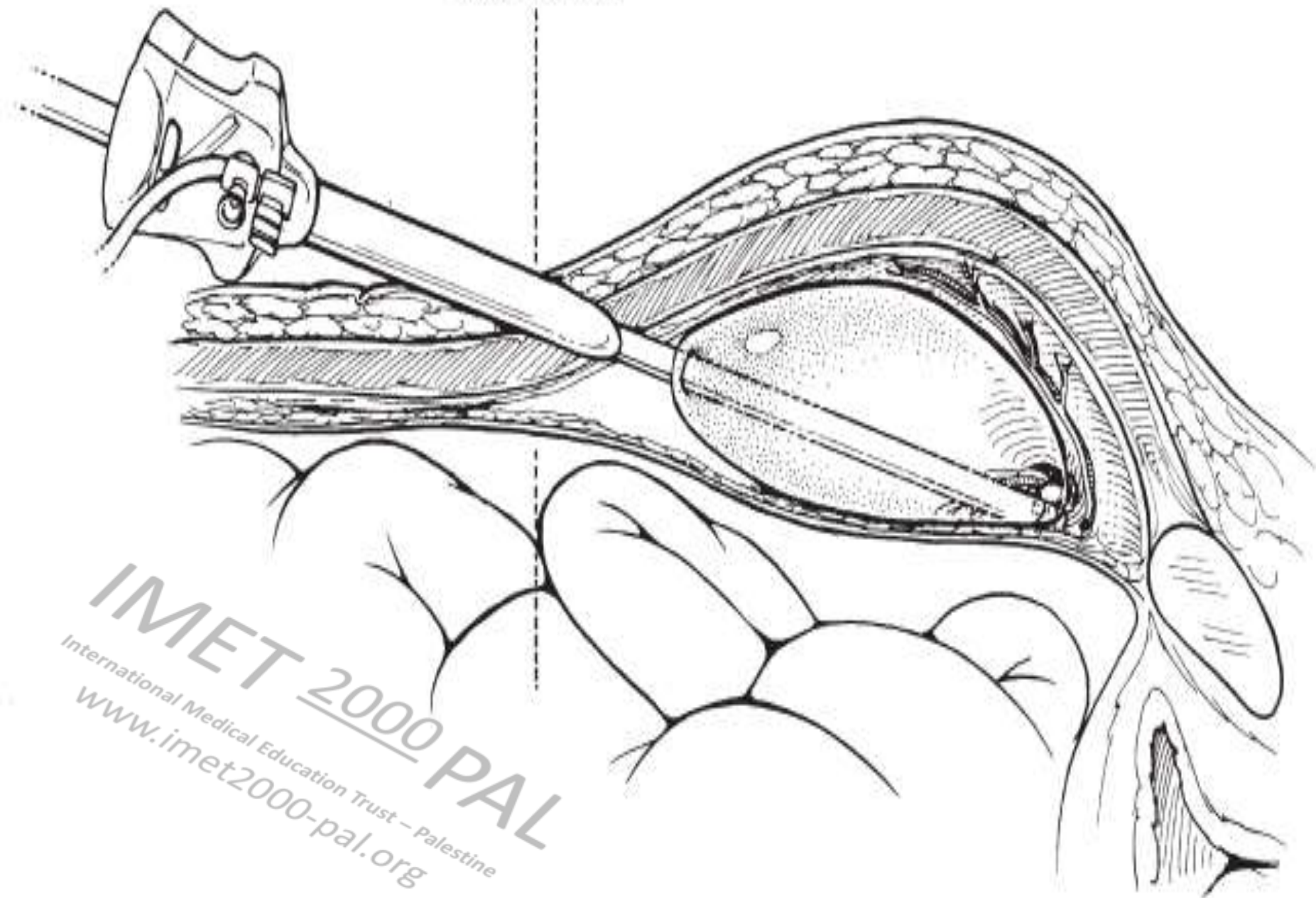
B



IMET 2000 PAL
International Medical Education Trust - Palestine
www.imet2000-pal.org

Fig. 53-3. The balloon dissector is placed on top of the posterior rectus sheath and advanced toward the pubis until the bone is palpated.

Arcuate line



IMET 2000 PAL
International Medical Education Trust – Palestine
www.imet2000-pal.org

IMET 2000 PAL

International Medical Education Trust – Palestine

www.imet2000-pal.org

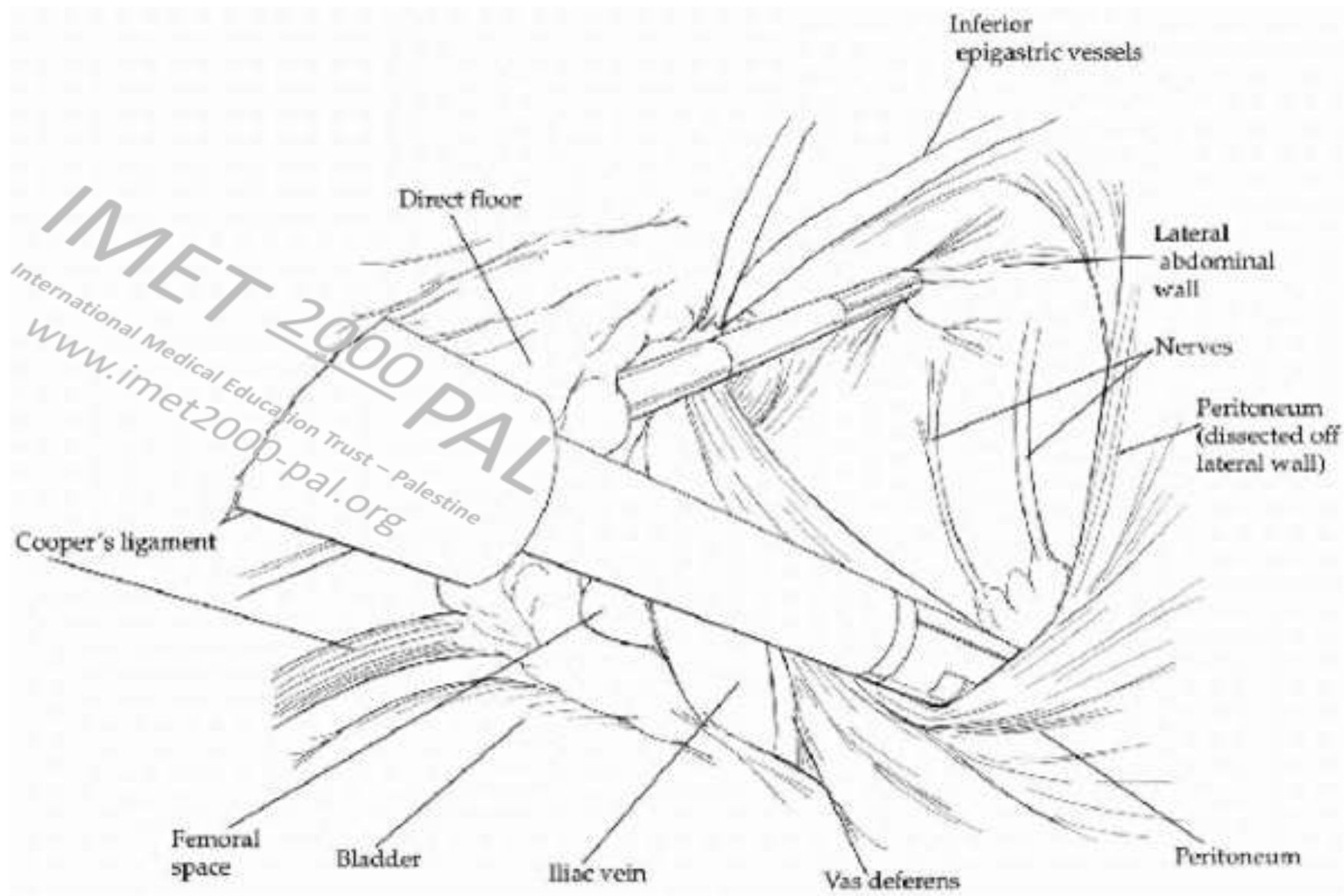
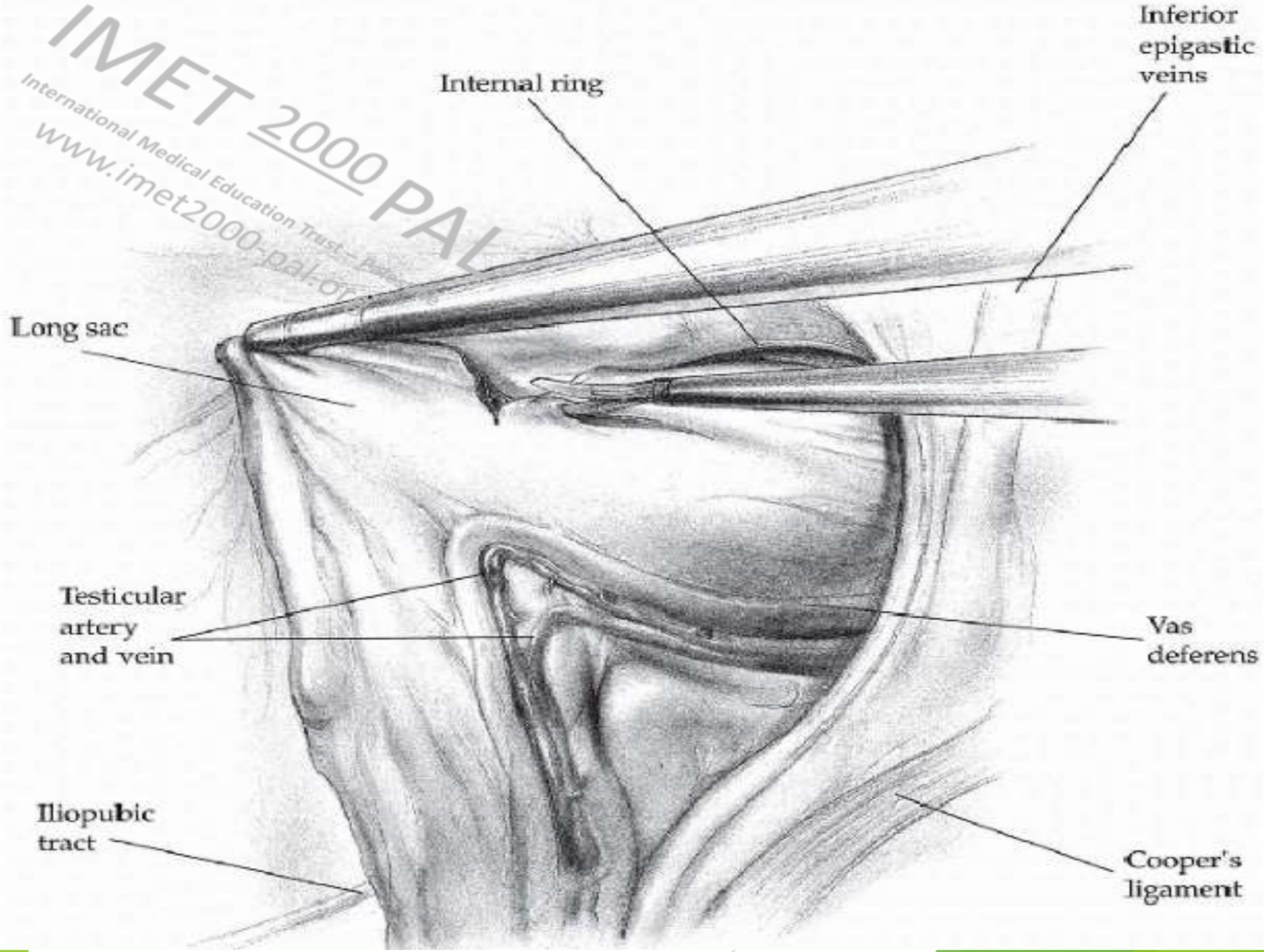


Fig. 53-10. The completed preperitoneal dissection exposing the cord, bony structures, and the lateral nerves.

An endoscopic view of a surgical site. A metallic surgical instrument, possibly a grasper or dissector, is visible on the left side, interacting with the tissue. The tissue is reddish and appears moist. The image is overlaid with text in the lower right quadrant.

IMET 2000 PAL
International Medical Education Trust - Palestine
www.imet2000-pal.org

IMET 2000 PAL
International Medical Education Trust - Palestine
www.imet2000-pal.org



Internal ring

Inferior epigastric veins

Long sac

Testicular artery and vein

Vas deferens

Iliopectic tract

Cooper's ligament

Top

6"

Superior

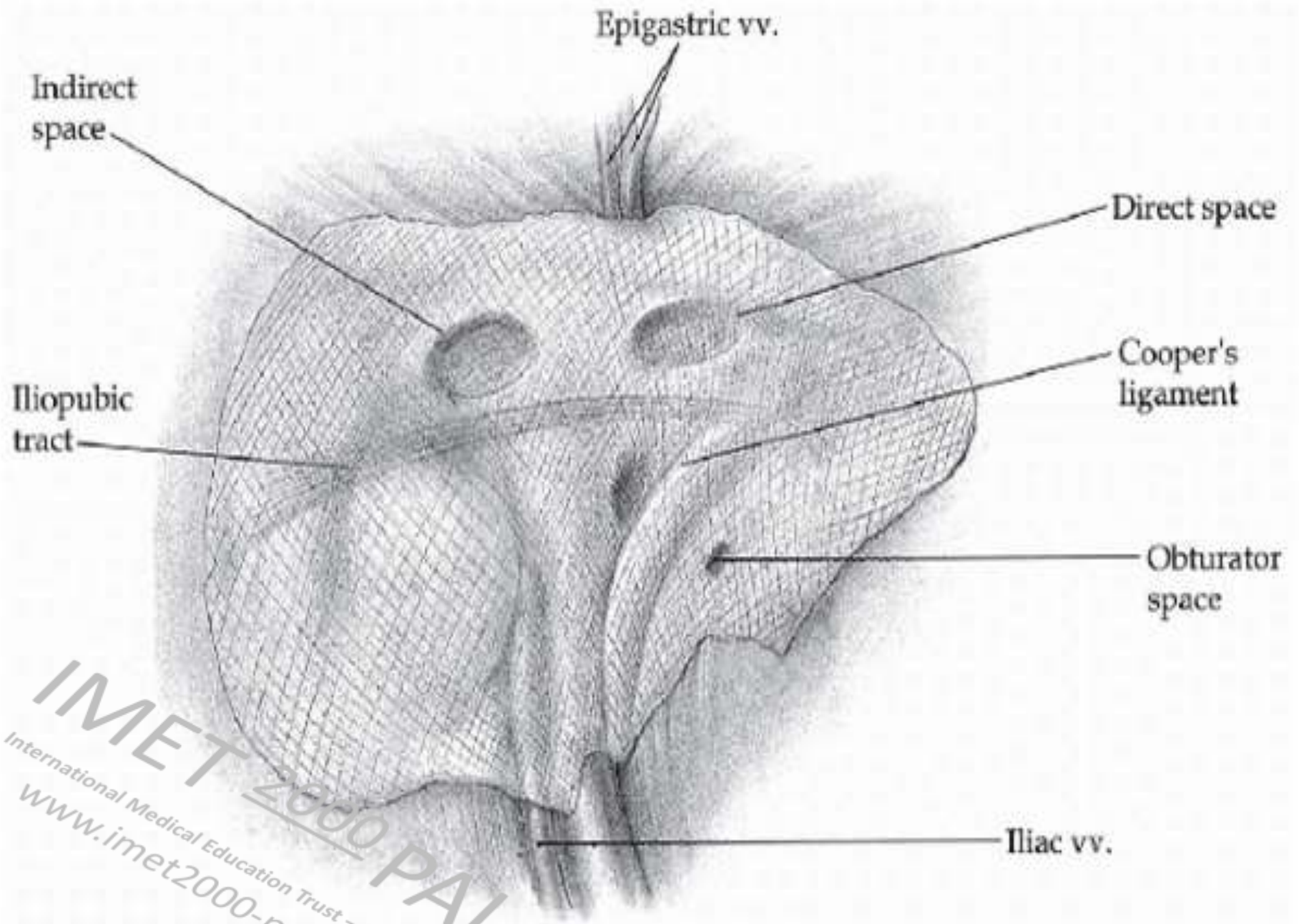
Lateral

Medial

Inferior

6"

INTERNET 2000 PAT
International Medical Education Trust - Palestine
www.internet-2000-pat.org





IMET 2000 PAL

International Medical Education Trust – Palestine
www.imet2000-pal.org

TAPP

IMET 2000 PAL
International Medical Education Trust – Palestine
www.imet2000-pal.org

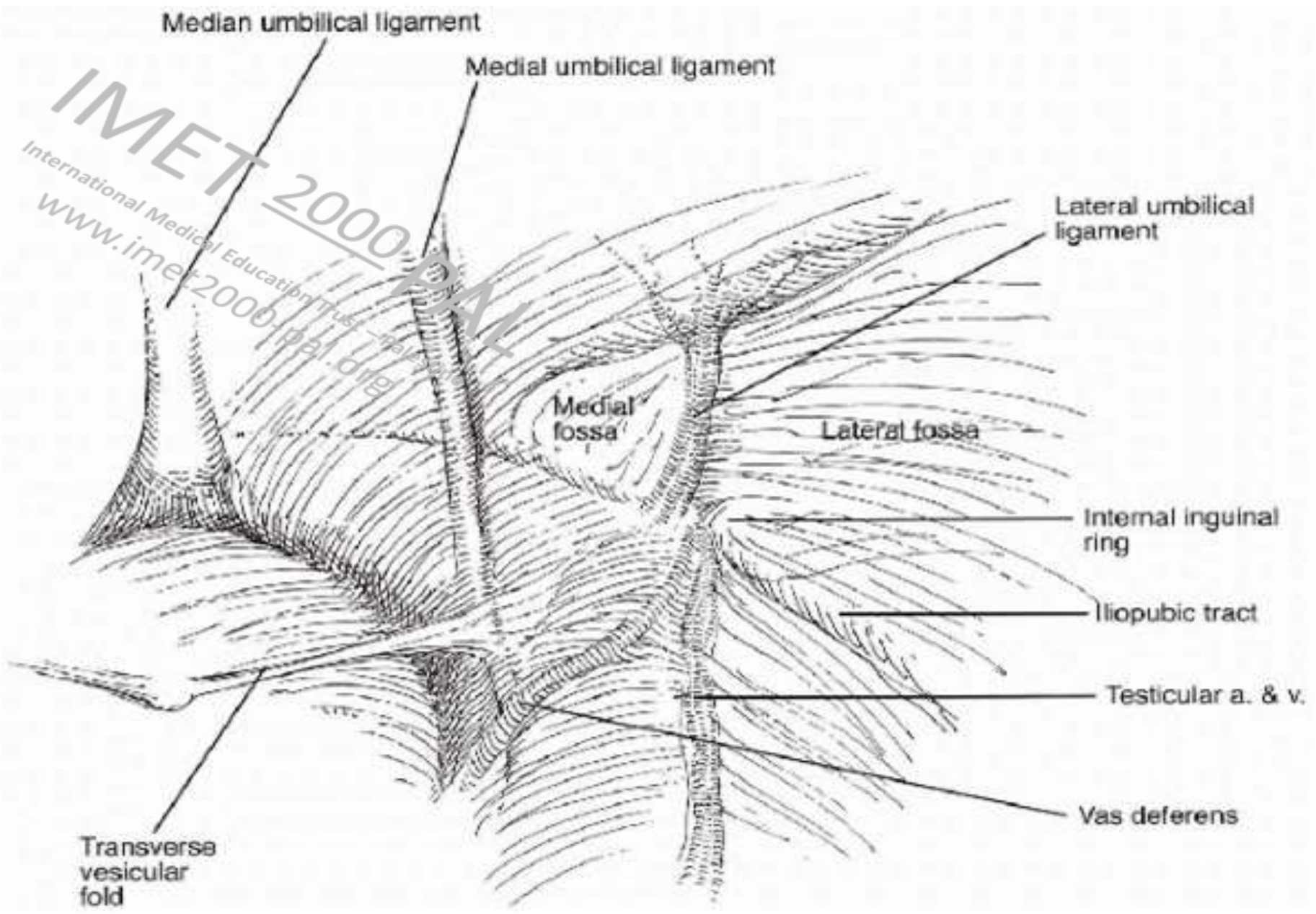


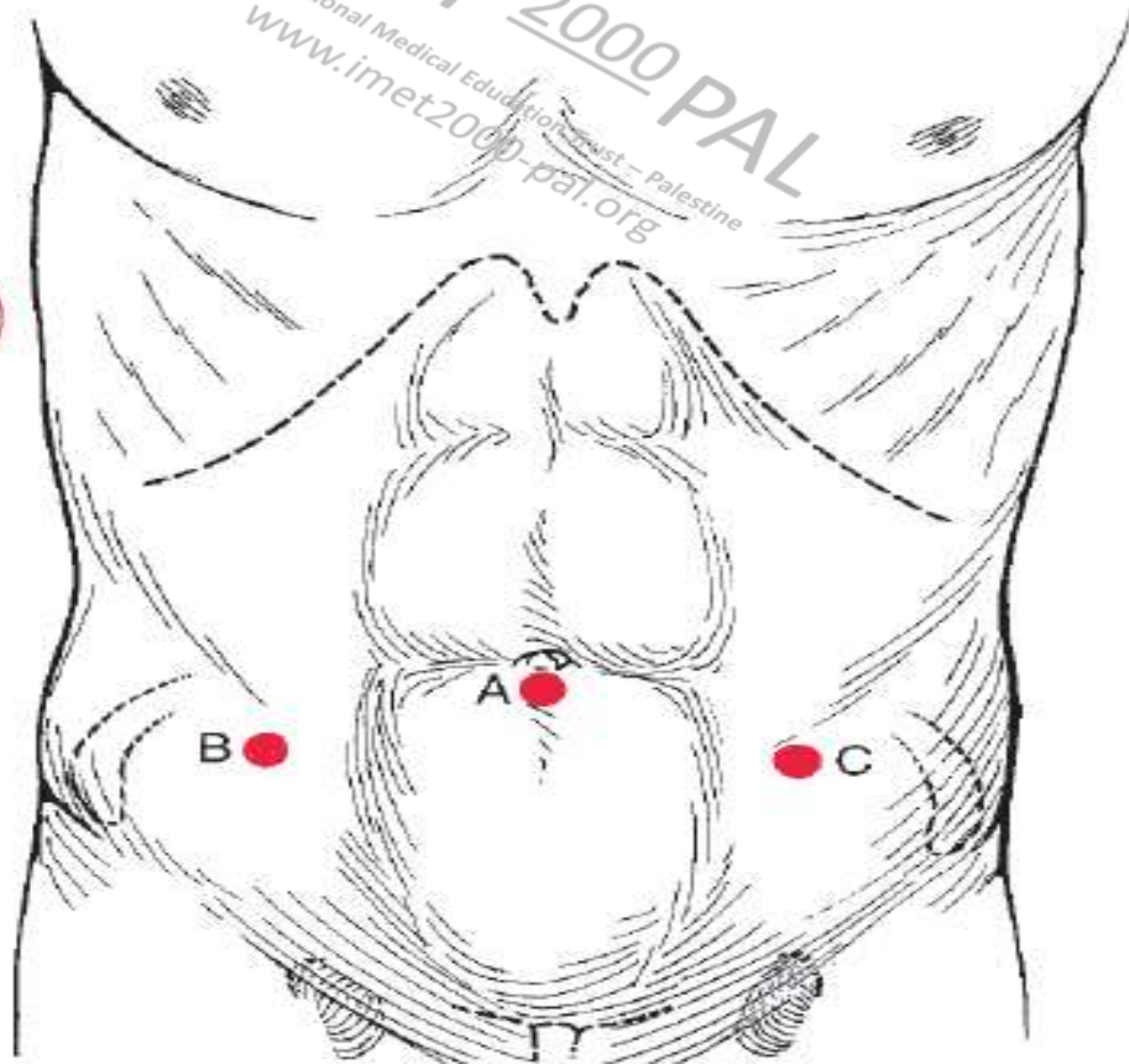
Fig. 53-14. Laparoscopic view and anatomy of right lower abdominal wall.

IMET 2000 PAL

International Medical Education Trust - Palestine
www.imet2000-pal.org

S

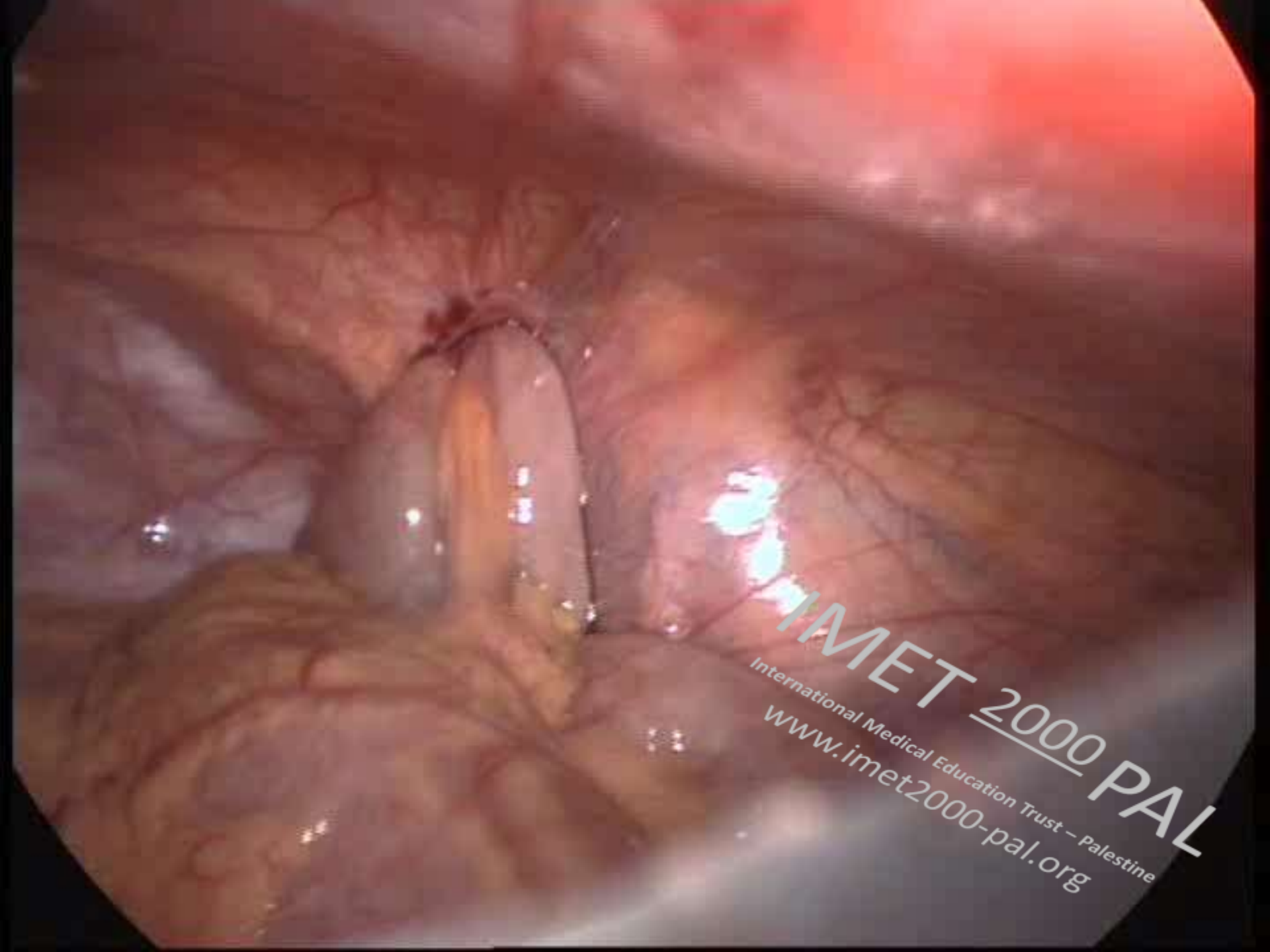
CA



A

B

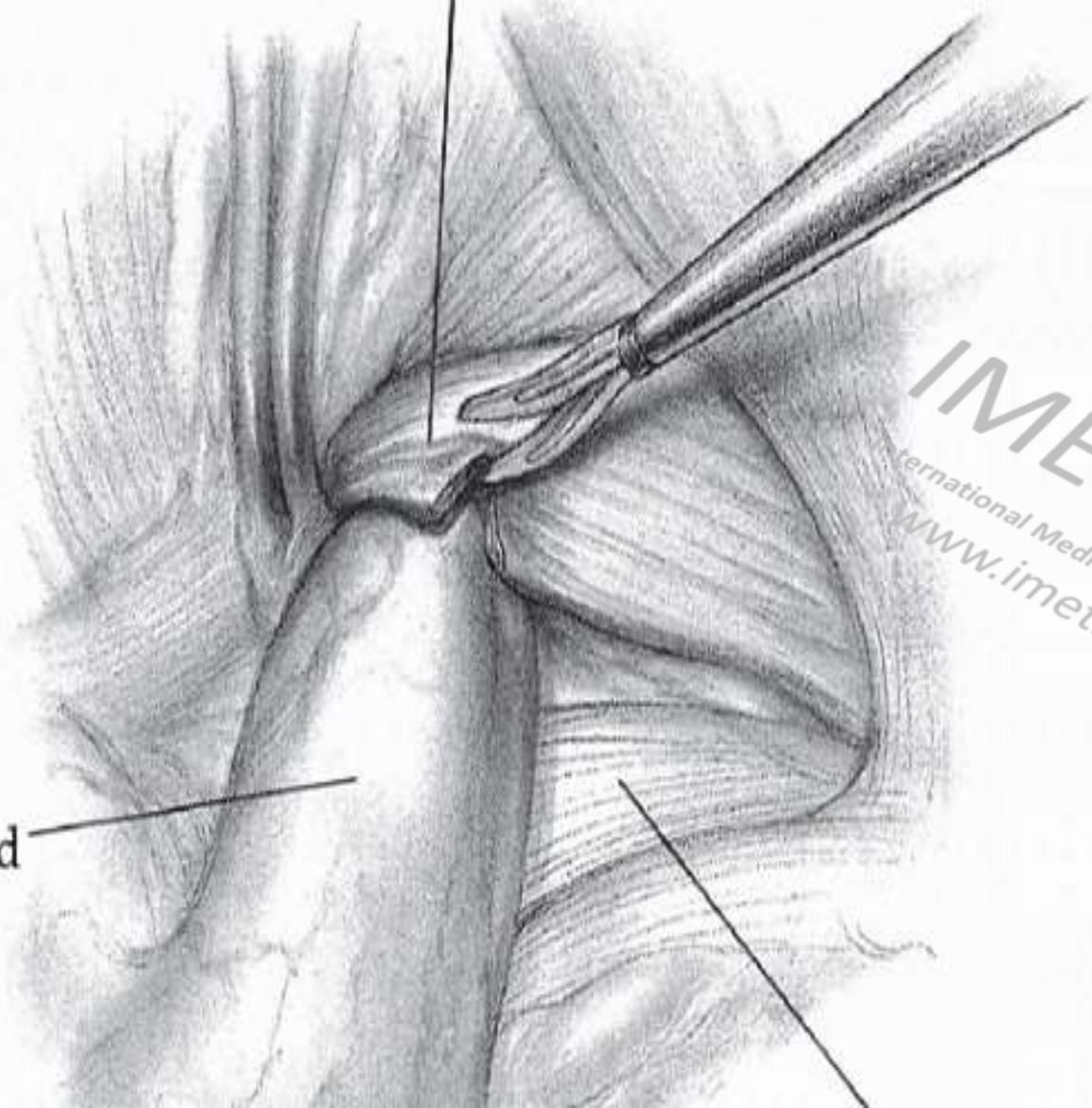
C



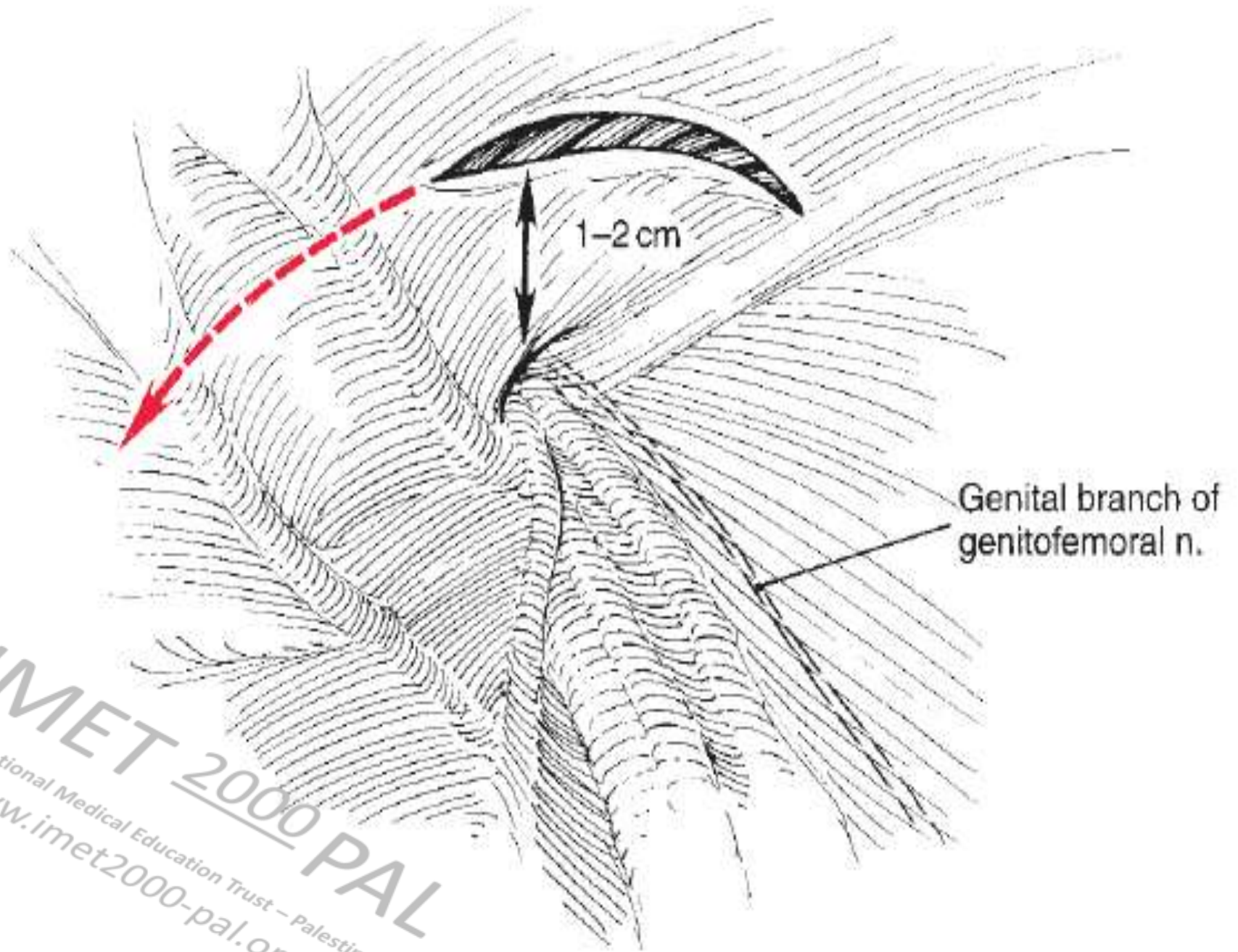
IMET 2000 PAL
International Medical Education Trust – Palestine
www.imet2000-pal.org

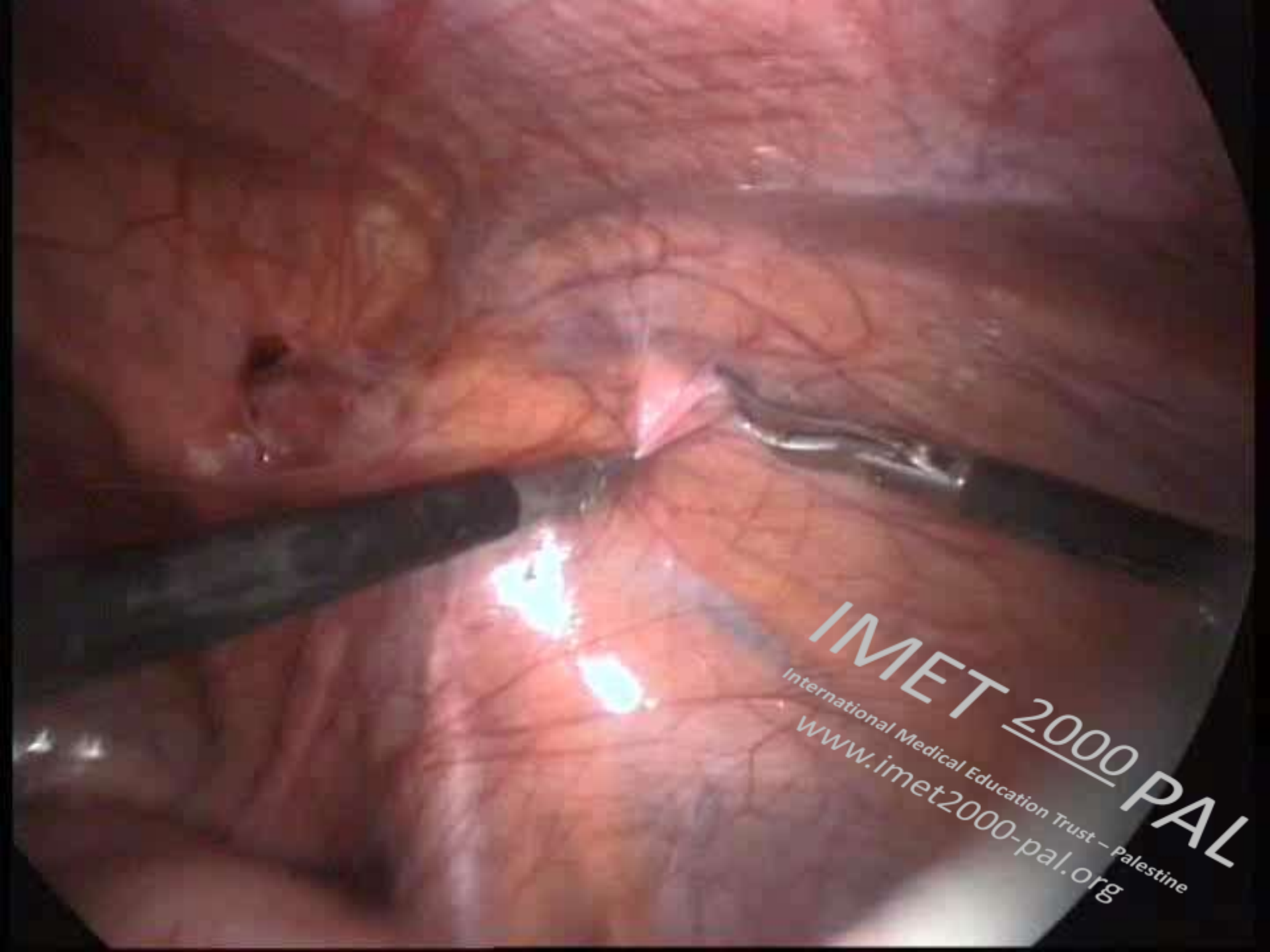
Femoral
ring

Incarcerated
femoral
hernia



IMET 2000 PAL
International Medical Education Trust - Palestine
www.imet2000-pal.org





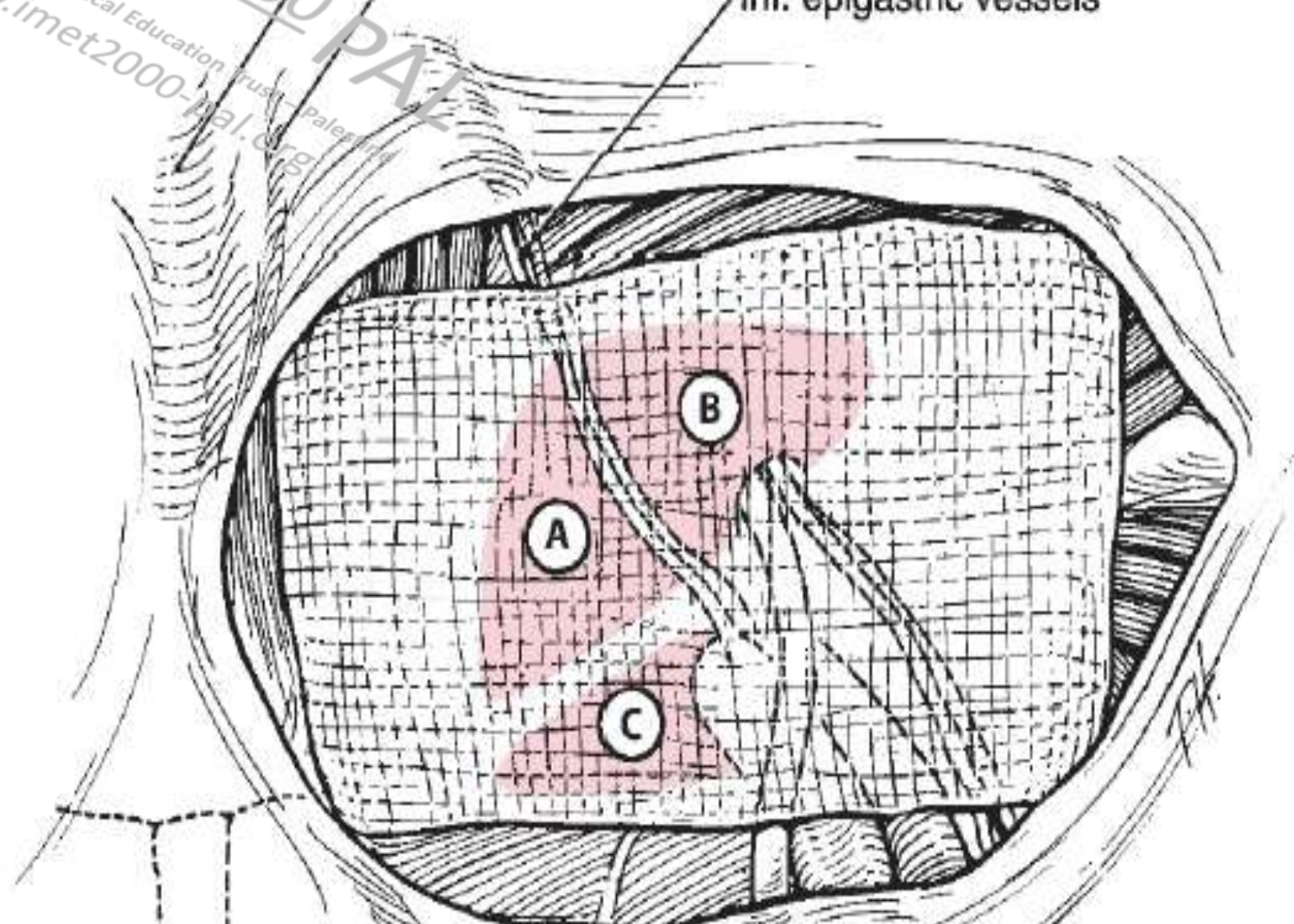
IMET 2000 PAL
International Medical Education Trust – Palestine
www.imet2000-pal.org

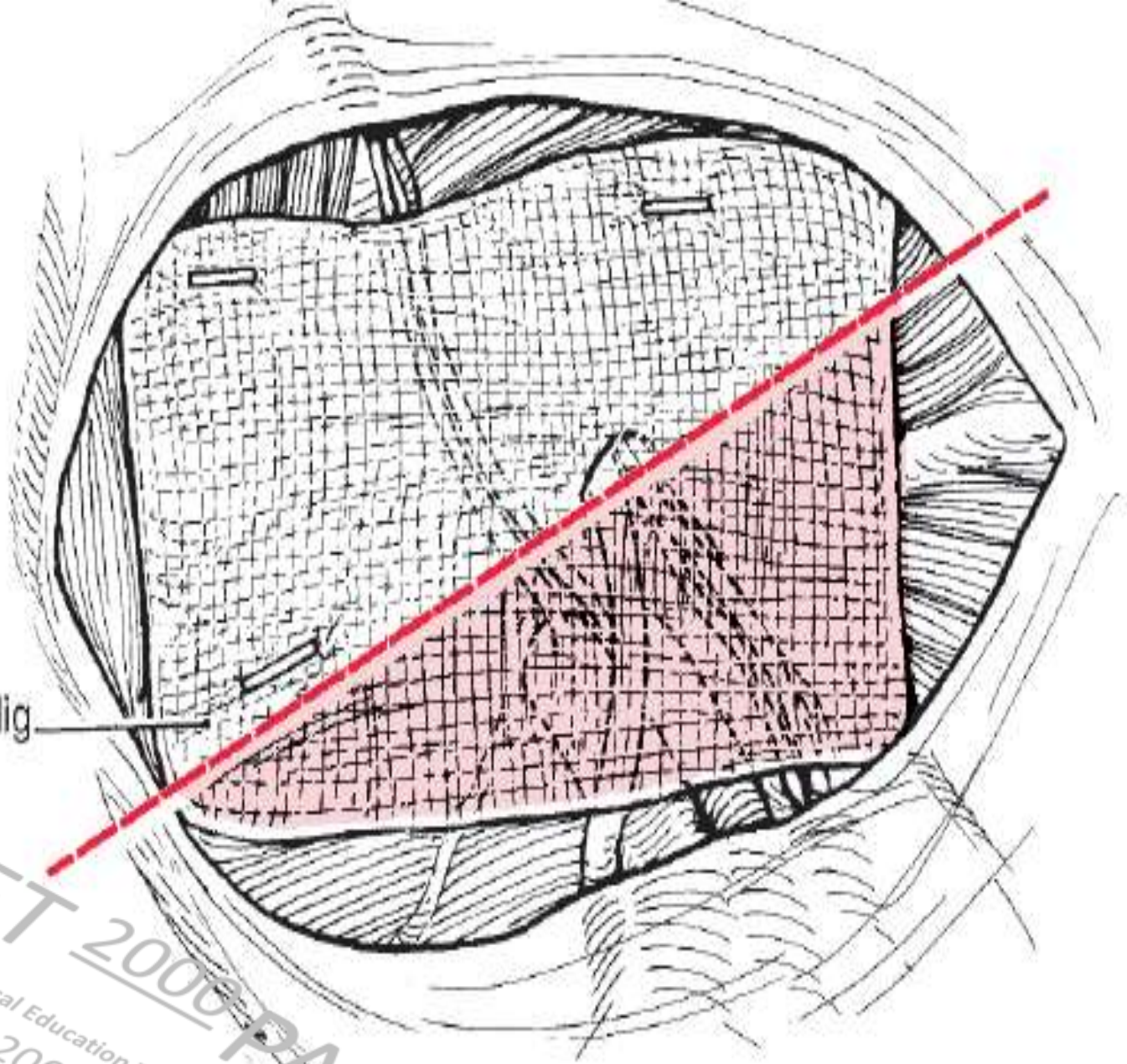
Uracus

Umbilical fold

Inf. epigastric vessels

IMET 2000 PAL
International Medical Education Trust - Palestine
www.imet2000-pal.org

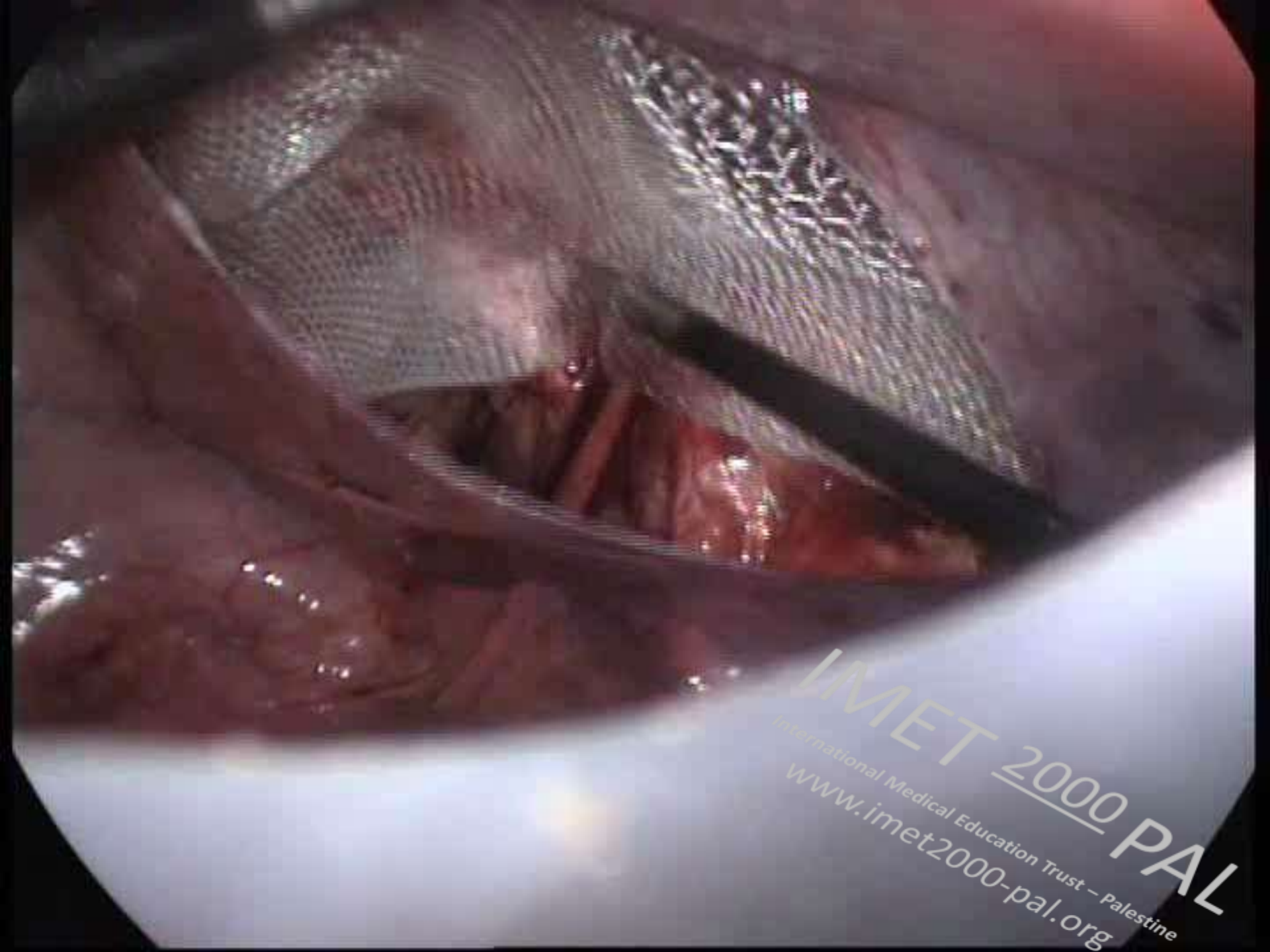




Cooper's lig

IMET 2000 PAL

International Medical Education Trust - Palestine
www.imet2000-pal.org



IMET 2000 PAL

International Medical Education Trust - Palestine
www.imet2000-pal.org

THANK YOU

IMET 2000 PAL
International Medical Education Trust – Palestine
www.imet2000-pal.org